

Erbium:Yttrium Aluminum Garnet Laser Treatment for Xanthelasma Palpebrarum

Su Young Jung
Na Hyun Hwang
Eul Sik Yoon
Seung Ha Park

*Department of Plastic & Reconstructive Surgery,
Korea University Anam Hospital, Seoul, Korea*

Xanthelasma palpebrarum is presented as a yellow plaque on the eyelids. Xanthelasma lesions are composed of fat cells that accumulate in the dermis and subcutaneous layer; progressive accumulation involves the orbicularis oculi muscle. Most patients with this condition request to have the lesion removed for cosmetic reasons, for which various treatment options are available, including surgical excision, chemical peeling, cryotherapy, argon laser, carbon dioxide (CO₂) laser, and neodymium:yttrium aluminum garnet (Nd:YAG) laser. Nevertheless, xanthelasmas are difficult to remove completely and has a high chance of recurrence. Recently, we were able to completely remove xanthelasma palpebrarum lesions in nine patients using erbium (Er):YAG laser. The Er:YAG laser seemed to maximize ablation effects, allowing us to easily determine whether the lesion had been completely removed. Moreover, we noted that, due to minor residual thermal damage, wound healing occurred rapidly with minimum side effects.

Key words

Xanthelasma palpebrarum; Erbium:yttrium aluminum garnet laser

Received May 19, 2017
Accepted May 22, 2017

Correspondence

Seung Ha Park
Department of Plastic & Reconstructive Surgery,
Korea University Anam Hospital, 73 Incheonro,
Seoul 02841, Korea
Tel.: +82-2-920-5440
Fax: +82-2-922-4291
E-mail: shp98@korea.ac.kr

© Korean Society for Laser Medicine and Surgery

© This is an open access article distributed under the terms of the Creative Commons Attribution Non-Commercial License (<http://creativecommons.org/licenses/by-nc/4.0>) which permits unrestricted non-commercial use, distribution, and reproduction in any medium, provided the original work is properly cited.

INTRODUCTION

Xanthelasma palpebrarum is a yellowish benign tumor that occurs on the eyelid. Lesions begin to develop at the medial part of the upper eyelid and grows, in some cases extending to the lower eyelid.^{1,2} Patients generally do not complain of pain or discomfort, but may request removal for cosmetic reasons. Xanthelasma palpebrarum is the most common form of xanthoma. Xanthelasma palpebrarum is composed of xanthoma or foam cells, both of which contain fat. These cells exhibit accumulation of histiocytes and can include cholesterol.³ Xanthelasma palpebrarum lesions first appear in the reticular dermis or subcutaneous tissue and gradually increase in thickness. Lesions can then spread to not only the subcutaneous layer, but also the orbicularis oculi muscle.

Various treatment options for xanthelasma palpebrarum are available, including surgical excision,^{4,5} chemical peeling,^{6,7} cryotherapy, argon laser,⁸ carbon dioxide (CO₂) laser,^{9,10} and neodymium:yttrium aluminum garnet (Nd:YAG) laser.^{11,12} However, the results thereof are generally suboptimal and involve high recurrence rates. Recently, a 2,940-nm erbium (Er):YAG laser has come into use for treating xanthelasma palpebrarum.¹³⁻¹⁶ The Er:YAG laser seems to eliminate xanthelasma palpebrarum more precisely than other techniques. Additionally, treatment with the laser enables wound healing with no residual scarring. Herein, we report on our use of an Er:YAG laser to treat xanthelasma palpebrarum and the results thereof in nine patients.

CASE REPORT

We analyzed nine patients (six females and three males; ages ranging from 42 to 50 years) who were treated with a 2,940-nm Er:YAG laser for xanthelasma palpebrarum. Diagnosis of xanthelasma palpebrarum was made according to distinctive clinical features thereof. At baseline, eight patients exhibited xanthelasma palpebrarum lesions on both eyelids; only one patient presented with unilateral xanthelasma palpebrarum. Seven patients had xanthelasmas only on the upper eyelid, while two patients showed lesions on both the upper and lower eyelids. The xanthelasmas appeared to have progressed differently in each patient: Three patients had lesions in the lower dermis and subcutaneous layer, five had full-thickness lesions, and one patient exhibited extension to the orbicularis oculi muscle. All patients had xanthelasmas on the medial upper eyelid; these were present for 6 months to 4 years before the patients came in for treatment. In one

patient with a lesion for 4 years, the xanthelasma progressed from the upper eyelid to the medial canthal area and lower eyelid. The widths of the lesions varied from 4 mm to 12 mm. No patient had systemic disease, and only two had an increased blood cholesterol level. No patients had a family history of xanthelasma.

The removal procedure was as follows. Anesthetic ophthalmic solution was applied, and a stainless metal eye shield was inserted to protect the cornea. The lesions were demarcated with a surgical marking pen (Fig. 1A), and anesthesia was administered with lidocaine hydrochloride at 2% and epinephrine at 1:100,000. Then, five to 20 passes were made with the 2,940-nm Er:YAG laser (Contour; Sciton, Palo Alto, CA, USA) at a 2-mm spot size in the 50-100 mJ ablation mode until the lesion was fully vaporized. As the Er:YAG laser beam is most effective on hydrophilic tissue, it was possible to both maximize vaporization and determine whether the xanthelasma was fully removed. The procedure was performed with a loupe to aid in recognition of removal. Bleeding during the procedure was stopped by switching the Er:YAG laser to the coagulation mode (Fig. 1B): if bleeding is severe, electrocoagulation can be performed; however, in most cases,

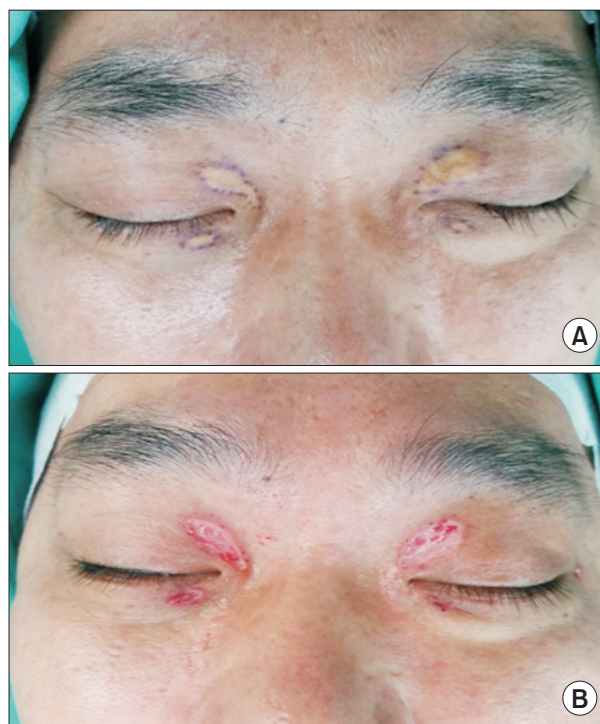

Fig. 1. A 42-year-old male (A) before and (B) immediately after laser removal of xanthelasmas on the upper and lower eyelids. Erbium:yttrium aluminum garnet (Er:YAG) laser generated little thermal damage and maximized vaporization, enabling easy recognition of degrees of removal.

moist gauze compression is adequate. After completely removing xanthelasma lesions with the laser, we applied a thin occlusive hydrocolloid dressing (DuoDERM CGF; ConvaTec, ER Squibb & Sons, Princeton, NJ, USA) until wound healing was completed.

Small xanthelasma lesion required 5 to 14 days for complete epithelialization (Fig. 2-4). No patient experienced recurrence on follow-up for 6 to 30 months, and erythema disappeared within 1 to 2 weeks. We recorded no hypertrophic scarring and no hyper- or hypopigmentation. After removal of the lesions with the laser, patients could fully close their eyes without ectropion; no contraction or lagophthalmos was observed.

DISCUSSION

Xanthelasmas consist of xanthoma cells or foam cells, which include fat elements. Inflammation and fibrosis can appear around the lesions. While the pathophysiology of this condition is not clearly understood, lesions are commonly seen in those with hyperlipidemia. Studies suggest that the likelihood of developing xanthelasmas may increase up to 50% in those with high total cholesterol and low-density lipoprotein levels. Moreover, xanthelasma may indicate underlying systemic disease, and when

accompanied by hyperlipidemia, hypertension, atherosclerosis, liver cirrhosis, hypothyroidism, or nephrotic syndrome, systemic care is needed, with medication, to lower hyperlipidemia.¹⁻³

Xanthelasmas do not resolve spontaneously. Over time, they gain color and become thicker and larger. Xanthelasmas start in the reticular dermis or subdermis and progress to the subcutaneous layer and orbicularis oculi muscle. Various treatment options are available including excision,^{4,5} trichloroacetic acid (TCA) peeling,^{6,7} cryotherapy, argon laser,⁸ CO2 laser,^{9,10} and Nd:YAG laser therapy.^{11,12} Small lesions can be effectively treated by surgical excision.⁵ If the lesion is large, however, direct closure can be difficult and contracture, ectropion, and eyelid deformities can develop. Because these usually occur in middle-aged individuals with redundant skin, eyelid contractures do not occur often. However, upper blepharoplasty may be needed for a drooping eyelid.⁴ If a defect is large after removal of a xanthelasma, a skin graft is occasionally performed. However, this is not recommended on the upper eyelid, because grafted skin on a mobile tissue can wrinkle easily.^{17,18} Peeling with 25-30% TCA is also used in some cases to unroof the skin. However, the depth of treatment is difficult to control with this method, making complete removal impossible. Moreover, serious compli-

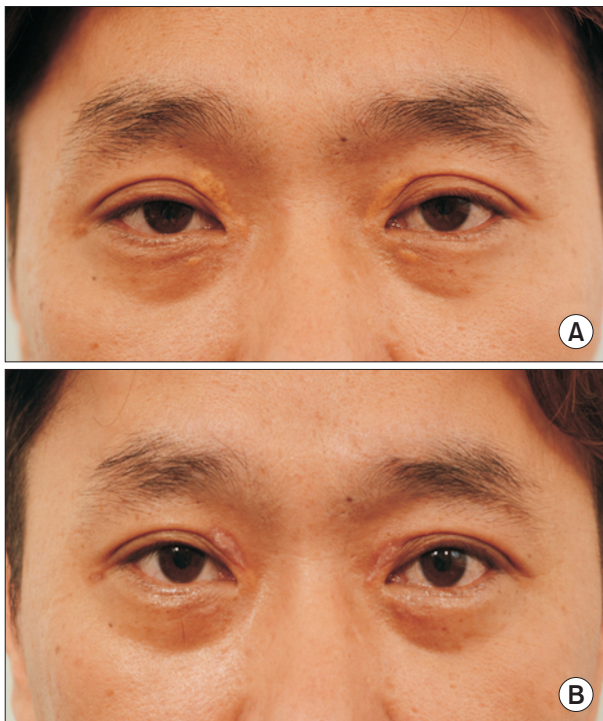


Fig. 2. Same treatment as that for the patient in Figure 1. (A) Before treatment and (B) 2 weeks after treatment.

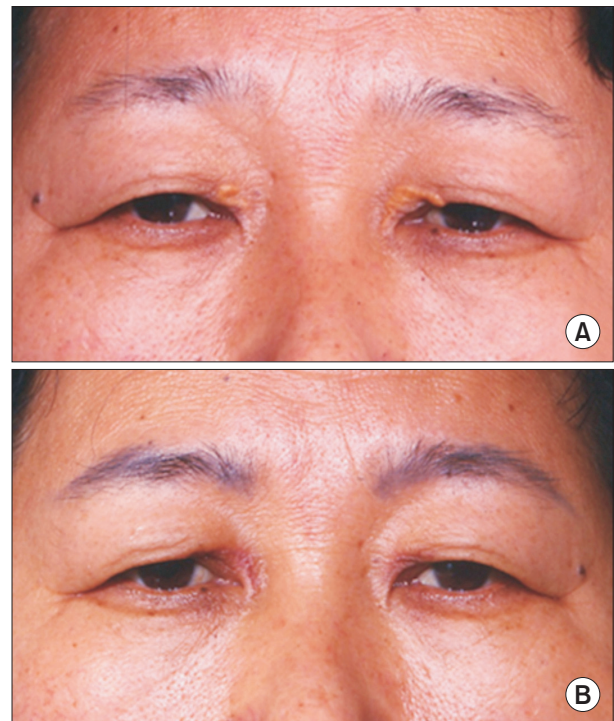


Fig. 3. A 60-year-old female patient (A) before and (B) 1 month after treatment of xanthelasmas on the upper eyelids.

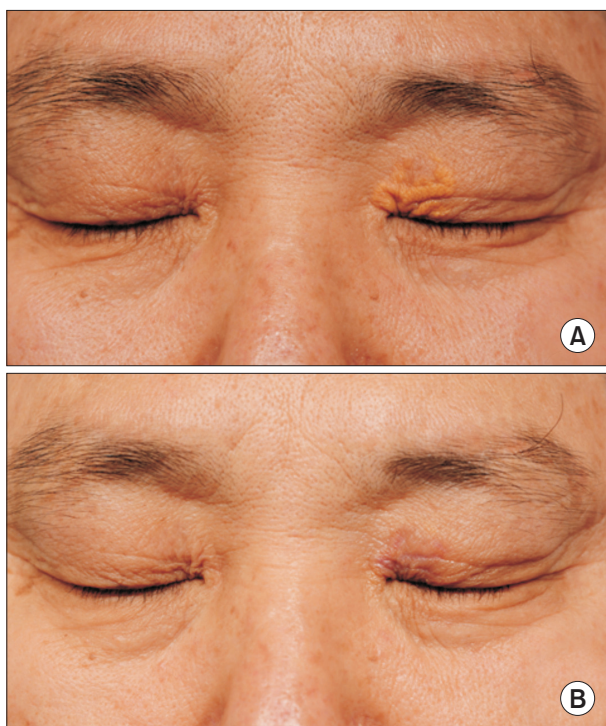


Fig. 4. (A) Before and (B) one month after Er:YAG laser treatment of unilateral xanthelasma. There were no signs of hypertrophic scarring or lagophthalmos.

cations, such as hypertrophic scar formation, contracture, and ectropion, can occur. A shallow chemical peel will not completely remove the lesion, which can recur, leading to multiple procedures. Cryotherapy is also used, but introduces problems similar to those with chemical peeling.

As stated above, several lasers have also been used to treat xanthelasma. Primitive lasers, such as argon and continuous mode CO₂ lasers, randomly coagulate skin and lesions with heat. As their treatment depth cannot be controlled, side effects are a concern. The Nd:YAG laser has a selective effect on pigmentation, but is not effective for xanthelasma.¹⁶ In the mid-1990s, the ultra-pulsed CO₂ laser was developed for skin lesion removal, and it can be applied for less than 1 msec for effective vaporization with high fluency.⁹ At first, we performed surgical excision to remove xanthelasmas; then, we changed to the ultra-pulsed CO₂ laser; and now, we use an Er:YAG laser. The water absorption coefficient of Er:YAG laser energy is 10 times greater than that of CO₂ laser energy. This maximizes tissue vaporization with less residual thermal effects, enabling rapid wound healing. Moreover, erythema, which is seen after CO₂ laser treatment, disappears quickly; post inflammatory hyperpigmentation is rare, and the down-time is less. The most significant reason

for the use of Er:YAG laser is that, unlike the CO₂ laser, with which detecting residual lesion tissue can be difficult, because of thermal effects and formation of char, the Er:YAG laser causes only mild residual thermal injury and no char formation, enabling complete removal of xanthelasmas.¹³⁻¹⁵

We believe that the Er:YAG laser provides the most effective treatment for xanthelasmas, because it completely removes eyelid xanthelasmas with a minimal recurrence rate and it is easy to administer. Common skin lesions on the eyelids of middle-aged women include syringomas and milia. These multiple small lesions occur in association with sweat and fat glands, and can also be removed with a laser. The Er:YAG laser can remove these small lesions with a small spot size and in the ablation mode. If a middle age person has minor wrinkles around the eyes, one can apply a combination of coagulation and ablation modes to remove skin lesions and wrinkles. This will improve skin elasticity and facilitate eyelid rejuvenation.

REFERENCES

1. Parkes ML, Waller TS. Xanthelasma palpebrarum. *Laryngoscope* 1984;94:1238-40.
2. Rohrich RJ, Janis JE, Pownell PH. Xanthelasma palpebrarum: a review and current management principles. *Plast Reconstr Surg* 2002;110:1310-4.
3. Bergman R. The pathogenesis and clinical significance of xanthelasma palpebrarum. *J Am Acad Dermatol* 1994;30:236-42.
4. Lee HY, Jin US, Minn KW, Park YO. Outcomes of surgical management of xanthelasma palpebrarum. *Arch Plast Surg* 2013;40:380-6.
5. Mendelson BC, Masson JK. Xanthelasma: follow-up on results after surgical excision. *Plast Reconstr Surg* 1976;58:535-8.
6. Cannon PS, Ajit R, Leatherbarrow B. Efficacy of trichloroacetic acid (95%) in the management of xanthelasma palpebrarum. *Clin Exp Dermatol* 2010;35:845-8.
7. Mourad B, Elgarhy LH, Ellakkawy HA, Elmahdy N. Assessment of efficacy and tolerability of different concentrations of trichloroacetic acid vs. carbon dioxide laser in treatment of xanthelasma palpebrarum. *J Cosmet Dermatol* 2015;14:209-15.
8. Hintschich C. Argon laser coagulation of xanthelasmas. *Ophthalmologie* 1995;92:858-61.
9. Raulin C, Schoenermark MP, Werner S, Greve B. Xanthelasma palpebrarum: treatment with the ultrapulsed CO₂ laser. *Lasers Surg Med* 1999;24:122-7.
10. Ahn KJ, Kang JS, Cho SB. Treatment of xanthelasma palpebrarum by the pinhole method using a 10,600-nm carbon

- dioxide laser. *Med Laser* 2013;2:70-2.
11. Fusade T. Treatment of xanthelasma palpebrarum by 1064-nm Q-switched Nd:YAG laser: a study of 11 cases. *Br J Dermatol* 2008;158:84-7.
 12. Karsai S, Schmitt L, Raulin C. Is Q-switched neodymium-doped yttrium aluminium garnet laser an effective approach to treat xanthelasma palpebrarum? Results from a clinical study of 76 cases. *Dermatol Surg* 2009;35:1962-9.
 13. Borelli C, Kaudewitz P. Xanthelasma palpebrarum: treatment with the erbium:YAG laser. *Lasers Surg Med* 2001;29:260-4.
 14. Lieb WE, Klink T, Münnich S. [CO₂ and erbium YAG laser in eyelid surgery. A comparison]. *Ophthalmologie* 2000;97:835-41. German.
 15. Mannino G, Papale A, De Bella F, Mollo R, Morgia P, Gabrieli CB. Use of Erbium:YAG laser in the treatment of palpebral xanthelasmas. *Ophthalmic Surg Lasers* 2001;32:129-33.
 16. Balevi A, Ustuner P, Ozdemir M. Erbium:yttrium aluminum garnet laser versus Q-switched neodymium:yttrium aluminum garnet laser for the treatment of xanthelasma palpebrarum. *J Cosmet Laser Ther* 2017;19:100-5.
 17. Yang Y, Sun J, Xiong L, Li Q. Treatment of xanthelasma palpebrarum by upper eyelid skin flap incorporating blepharoplasty. *Aesthetic Plast Surg* 2013;37:882-6.
 18. Kose R. Treatment of large xanthelasma palpebrarum with full-thickness skin grafts obtained by blepharoplasty. *J Cutan Med Surg* 2013;17:197-200.

